

A Prospective Study on Immediate Loading of Dental Implants

Khoury F.**, Becker C.**, Hanser T.**, Berger F.**, Neugebauer J.*

* University to Cologne, Germany
** Clinic Schloss Schellenstein, Olsberg, Germany



Introduction

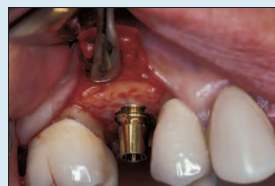High success rates, progress in therapy and technical innovations provided cause for accelerate implant protocols. The presentation reports the results of a study evaluating the clinical performance of immediate loading of dental implants.

Materials and Methods

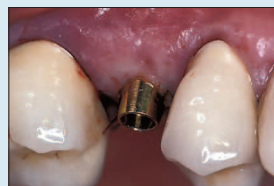Between 1999 and 2001 210 XiVE® screw-type implants with a grit-blasted and acid-etched surface were consecutively placed in 62 patients and immediately loaded having a placement torque of minimum 35 Ncm. 186 were placed in the mandible and 24 in the maxilla. Most of these implants were inserted in the interforaminal area of the mandible (172 implants), restored with a bar and overdenture and functionally loaded. 31 implants mainly in the esthetic area of the maxilla were immediately restored but without functional loading (out of occlusion), most of them for single-tooth restoration.



The XiVE® screw implant with a grit-blasted and acid-etched surface in different diameters (D 3.4, 3.8, 4.5, 5.5) and the color-coded XiVE® TempBase serving as an implant holder, placement head and temporary abutment for provisional restorations.



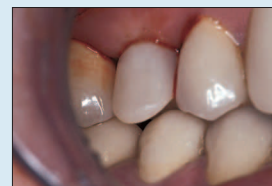
All implant placement a torque of 35 Ncm should be ensured for sufficient primary stability for immediate loading.



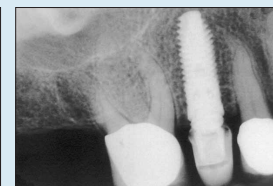XiVE® TempBase screw-retained with the implant after flap repositioning.



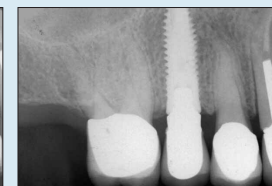
Mounting of a chairside fabricated composite cap on XiVE® TempBase. The prefabricated sleeve is filled up with composite and positioned over the cap intraorally.



Non-functionally loaded provisional restoration (out of occlusion) fixed with provisional cement on XiVE® TempBase.

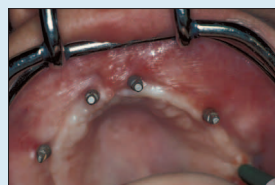

Radiograph taken immediately after implant placement and provisional restoration.

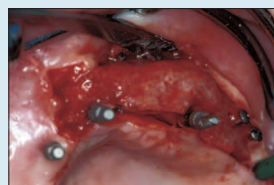


Radiograph of the final restoration taken one year after implant placement.

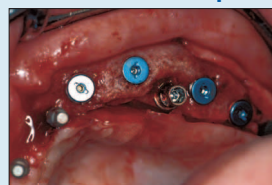Single Tooth



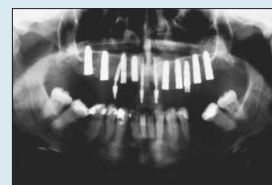
Four interim implants in the maxilla for a fixed temporary anterior bridge in connection with a block augmentation with iliac bone.



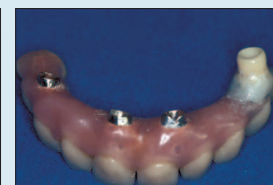Four months after the augmentation one interim implant is movable and has to be removed.



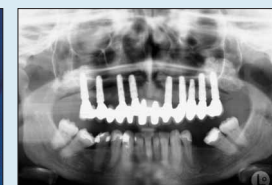XiVE® implant inserted in place of the lost interim implant for immediate functional loading in connection with the remaining interim implants.



Radiograph taken immediately after implant insertion.

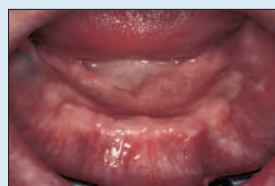

The existing interim restoration can easily be altered using a chairside fabricated composite cap for the new implant.

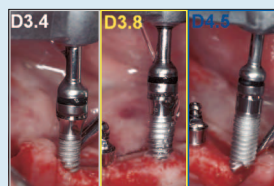


Radiograph of the final restoration taken one year after implant placement. The functionally loaded XiVE® implant is still in function and is incorporated into the final restoration.

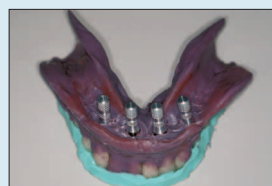Complex Restoration



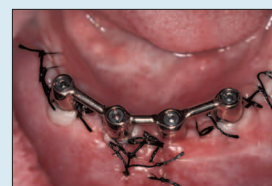
Clinical situation of the edentulous mandible before implant insertion.



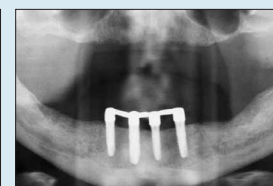Insertion of the XiVE® TG implants with a structure-polished gingival collar and endosseous design analogous to XiVE® implant.



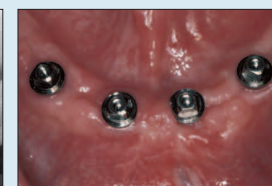The existing functional prosthesis is used for the impression. To produce a master model, the transfer impression coping is mounted on the implant analog and resetted back into the impression.



The clinical situation of the bar on four XiVE® TG implants. The denture is fixed with three matrices on the bar on the day of surgery.

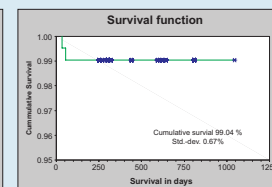
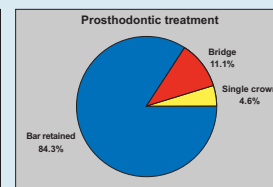
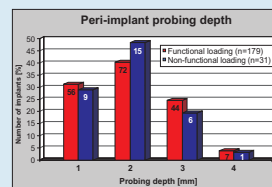
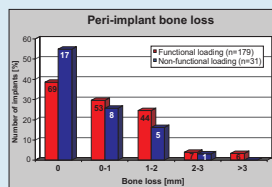
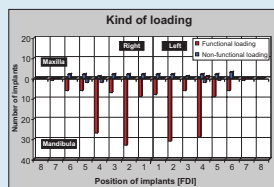
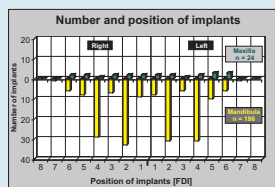


Panoramic radiograph after three months at first time of bar removal and check of osseointegration.



Healthy soft tissue after three months with stable implants in place. Easy hygiene due to transgingival placement of implant abutment connection.

Edentulous Mandible



Discussion

The data and the experience described of this 3-year analysis indicate that immediate loading of implants using appropriate surgical and restorative techniques can be a predictable technique for shortening dental rehabilitation time with relevant satisfaction for patients in restricted indications. Immediate restoration of implants in the esthetic area without functional loading seems to be a successful method in cases of implants with a high primary stability.

Results

After a follow-up of 12 to 36 months (average 27.3 months) 2 implants failed in the edentulous mandible, both during the first 2 months of loading. All other implants are still in function with acceptable peri-implant parameters. Bone loss > 3 mm was observed in 6 implants placed in the edentulous mandible. The 31 non-functionally loaded implants osseointegrated

and were restored with a functionally loaded ceramic crown 3 months after implant placement. Peri-implant probing depth and bone loss showed no significant difference between functional and non-functional implant loading.

References

- Ledermann PD. Siegprothetische Versorgung des zahllosen Unterkiefers mit Hilfe von plasmabeschichteten Tienschraubenimplantaten. Dtsch Zahnärztl Z 1979; 34: 907-911.
- Bränemark P-I, Hansson BO, Adell R, Breine U, Linström J, Hallén O. Osseointegrated implants in the treatment of the edentulous jaw. Experience of a 10-year period. Scand J Plast Reconstr Surg 1977; 16:1-132.

International Congress on
Reconstructive Preprothetic Surgery Meeting
Palm Springs, California
April 5-7, 2003

Prof. Dr. Fouad Khoury
Privatpraktik Schloss Schellenstein
Am Schellenstein 1, 59939 Olsberg, Germany
Phone: +49292237190
E-Mail: prof.khoury@online.de